



What is Your Radiologic Diagnosis?

Radyolojik Tanınız Nedir?

Gözde Özer (ID), Mithat Haliloğlu (ID)

Department of Radiology, Division of Pediatric Radiology Branch, Hacettepe University Faculty of Medicine, Ankara, Türkiye

Cite this article as: Özer G, Haliloğlu M. What is your radiologic diagnosis? J Pediatr Inf 2022;16(2):e127-e129.

A 14-year-old female patient presents to a family physician for fatigue, nausea, and shortness of breath ongoing for three months. Physical examination reveals decreased breath sounds in the right lung, and the patient is referred to hospital. The physical examination performed in the pediatric outpatient service of our hospital shows decreased breath sounds in the right lung and rales in the right lung

apex. Chest radiograph demonstrates a large opacity that effaces the right hemidiaphragm in the middle and lower zones of the right lung (Figure 1A). Computed tomography (CT) shows thick-walled cystic lesions in the lower lobe of the right lung and right lobe of the liver (asterisk) (Figure 1B), and these are evaluated as hydatid cysts lesions. Interventional radiology performs percutaneous drainage/

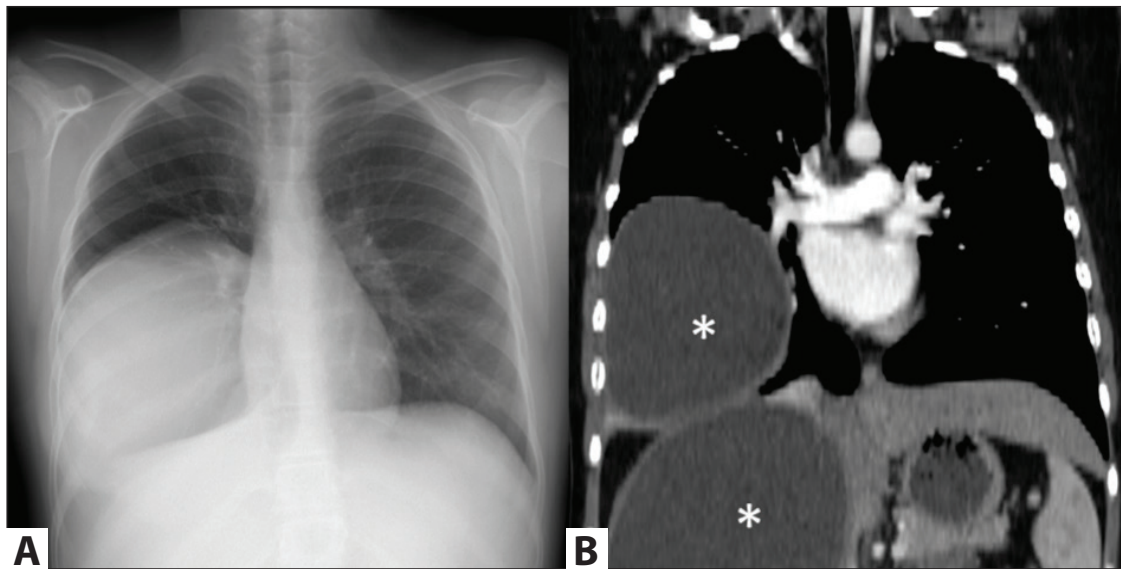


Figure 1. Posteroanterior chest radiography (A) and coronal reformat images (B) of the chest CT.

Correspondence Address/Yazışma Adresi

Gözde Özer

Hacettepe Üniversitesi Tıp Fakültesi,
Radyoloji Anabilim Dalı,
Pediatrik Radyoloji Bilim Dalı
Ankara-Türkiye

E-mail: gozdetufan@gmail.com

Received: 05.05.2022

Accepted: 23.05.2022

Available Online Date: 30.06.2022

©Copyright 2022 by Pediatric Infectious Diseases and Immunization Society.
Available online at www.cocukenfeksiyon.org

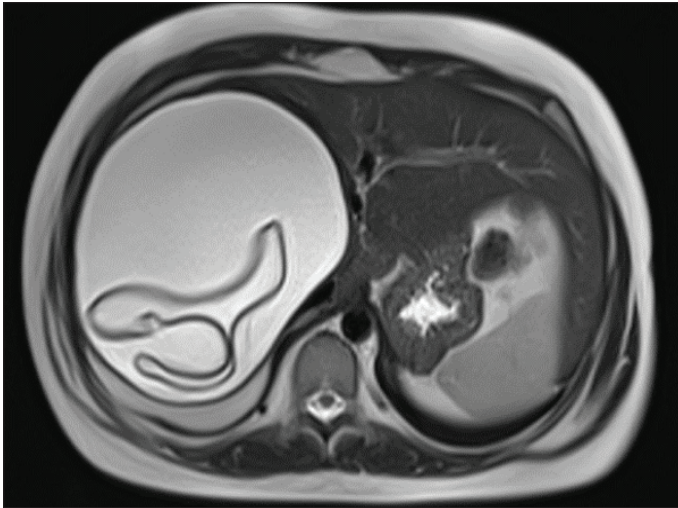


Figure 2. Axial T2-weighted MR image.

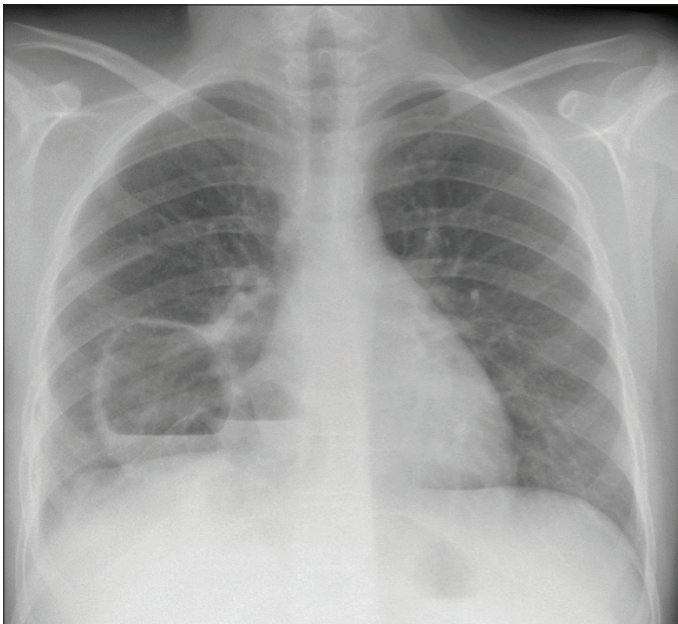


Figure 3. Posteroanterior chest radiography.

ablation to the lesion detected in the right lobe of the liver, and control magnetic resonance imaging indicates separated germinal layer (Figure 2). The lesion detected in the right lung is surgically removed. The patient, whose postoperative findings are normal, is discharged with albendazole treatment. The patient presents to the pediatric emergency of our hospital two months after surgery with complaints of fever and cough. Physical examination shows decreased breathing sounds in the right lung and the liver is palpable 4 cm below costal margin. Pulse is 158 pulse/min and body temperature is 37.7°C on presentation, and other vitals are normal. Laboratory tests indicate an increase in C-reactive protein and erythrocyte sedimentation rate (CRP= 46.5 mg/dL, ESR= 34 mm/h) and leukocytosis (WBC= $17.7 \times 10^3/\mu\text{L}$). Chest radiography shows bilobulated cavitory lesions with air-fluid level in the right lower zone (Figure 3). Chest CT detects collection with air-fluid level and thick wall in the lower lobe of the right lung (Figure 4). What is your diagnosis for the patient whose chest radiography and thoracic CT images are given?

Diagnosis: Postoperative Abscess in the Localization of the Operation Performed Due to Pulmonary Cyst Hydatid

Short Discussion

Cyst hydatid is a parasitic infectious disease caused by *Echinococcus granulosus* and is still endemic for Türkiye. It can effect any organ in the body, but it most frequently causes infection in the liver and the lungs. In the literature, synchronous involvement of the liver and the lung has been reported as 10-20% (1). Because of compressible structure of the lung, hydatid cyst lesions can reach large sizes; however, patients are mostly asymptomatic. Large lesions present with symptoms such as chest pain, dyspnea, cough, fever, and hemoptysis (2). Complications such as cyst rupture, anaphylaxis, compression of the adjacent anatomic structures, infection of the cyst, intrabronchial perforation, or pneumothorax can be seen (2).

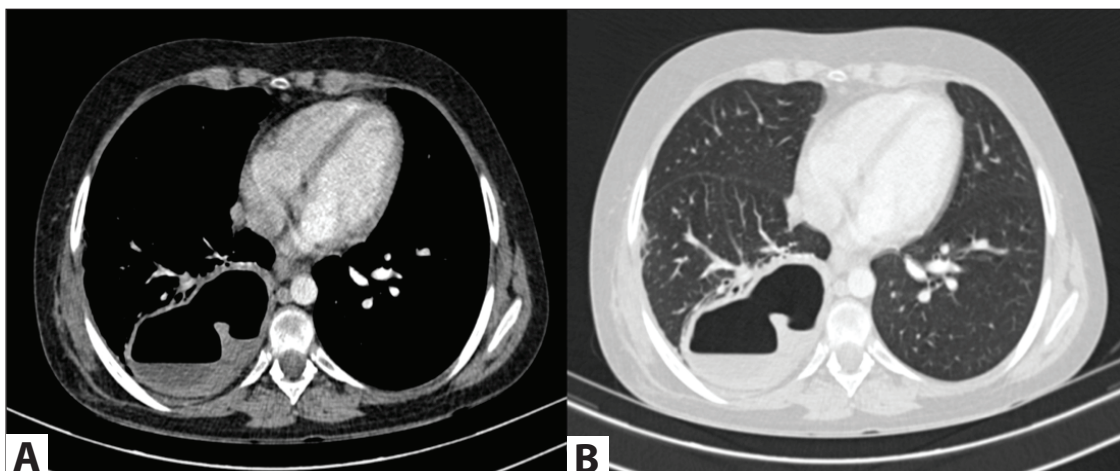


Figure 4. Axial chest CT on the mediastinum window (A) and parenchyma window (B).

Radiology plays a vital role in the diagnosis of asymptomatic lesions and complications. Chest radiography and chest CT are used in the evaluation of pulmonary cyst hydatid. Uncomplicated lesions can be seen as well-defined nodular opacities on chest radiograph (3). Complicated cyst hydatid, on the other hand, has varying findings. As a result of erosion of the bronchial wall by the cyst, air enters between the pericyst and delaminated membrane, and “meniscus sign” is seen on the chest radiograph. If air continues to enter the cyst cavity, the endocyst and pericyst totally separate and the collapsed endocyst forms a “lotus sign” (3). On chest CT, non-complicated lesions can be seen as cysts with and enhanced wall structure. CT can detect separated membranes or daughter cysts. Ultrasonography is also frequently used in pediatric patients in order to evaluate the content of the cyst. Unlike liver lesions, calcification is rare in lung lesions (3).

First treatment choice in cyst hydatid is mostly surgery (4). The most common operation-related complications are prolonged air leak, pneumonia, empyema, and wound site infections (5). Less frequently, recurrent cyst hydatid and lung abscess can be seen (6). In the differential diagnosis of surgical complications, radiologic imaging is beneficial besides symptoms and laboratory findings. In the presence empyema

or abscess, imaging-guided sampling and drainage can be performed in addition to appropriate antibiotic therapy. Less frequently, surgery can be required in the treatment of complications (6).

References

1. Celik M, Senol C, Keles M, Halezeroglu S, Urek S, Hacıbrahimoglu G, et al. Surgical treatment of pulmonary hydatid disease in children: Report of 122 cases. *J Pediatr Surg* 2000;35:1710-3. [\[CrossRef\]](#)
2. Kuzucu A, Soysal O, Ozgel M, Yologlu S. Complicated hydatid cysts of the lung: Clinical and therapeutic issues. *Ann Thorac Surg* 2004;77:1200-4. [\[CrossRef\]](#)
3. Polat P, Kantarci M, Alper F, Suma S, Koruyucu MB, Okur A. Hydatid disease from head to toe. *Radiographics* 2003;23:475-537. [\[CrossRef\]](#)
4. Velasco-Tirado V, Alonso-Sardón M, Lopez-Bernus A, Romero-Alegría Á, Burguillo FJ, Muro A, et al. Medical treatment of cystic echinococcosis: Systematic review and meta-analysis. *BMC Infect Dis* 2018;18:306. [\[CrossRef\]](#)
5. Usluer O, Ceylan KC, Kaya S, Sevinc S, Gursoy S. Surgical management of pulmonary hydatid cysts: Is size an important prognostic indicator? *Tex Heart Inst J* 2010;37:429-34.
6. Tullu MS, Lahiri KR, Kumar S, Oak SN. Minimal access therapy in pediatric pulmonary hydatid cysts. *Pediatr Pulmonol* 2005;40:92-5. [\[CrossRef\]](#)