



# The Efficacy of Long-Term Voriconazole Prophylaxis on Seven Patients with Chronic Granulomatous Disease and Review of the Literature

Kronik Granulomatoz Hastalıklı Yedi Hastada Uzun Dönem Vorikonazol Profilaksinin Etkisi ve Literatürün Gözden Geçirilmesi

Şeyhan Kutluğ<sup>1</sup>(iD), Şefika İlknur Kökçü Karadağ<sup>2</sup>(iD), S. Gülnar Şensoy<sup>3</sup>(iD), Asuman Birinci<sup>4</sup>(iD), Mustafa Yavuz Köker<sup>5</sup>(iD), Alişan Yıldırım<sup>2</sup>(iD)

<sup>1</sup> Clinic of Immunology and Allergy, Batman Gynecology and Child Diseases Hospital, Batman, Turkey

<sup>2</sup> Division of Pediatric Immunology and Allergy, 19 Mayıs University Faculty of Medicine Hospital, Samsun, Turkey

<sup>3</sup> Division of Pediatric Infectious Diseases, 19 Mayıs University Faculty of Medicine Hospital, Samsun, Turkey

<sup>4</sup> Department of Microbiology, 19 Mayıs University Faculty of Medicine Hospital, Samsun, Turkey

<sup>5</sup> Department of Immunology, Erciyes University Faculty of Medicine Hospital, Samsun, Turkey

**Cite this article as:** Kutluğ Ş, Kökçü Karadağ Şİ, Şensoy SG, Birinci A, Köker MY, Yıldırım A. The efficacy of long-term voriconazole prophylaxis on seven patients with chronic granulomatous disease and review of the literature. J Pediatr Inf 2021;15(4):e203-e209.

## Abstract

**Objective:** Chronic granulomatous disease (CGD) a primary immunodeficiency disease that affects the innate immune system, and characterized by life-threatening and/or recurrent infections caused by bacteria and fungi. Invasive fungal diseases (IFDs) are the most common causes of death among CGD patients. Itraconazole is usually used for prophylaxis in CGD patients at high risk of IFD. However, patient compliance with oral itraconazole use is low due to gastrointestinal side effects. We aim to report the efficacy of long-term voriconazole prophylaxis for IFD on our CGD patients.

**Material and Methods:** This retrospective study includes seven CGD patients. All data were recorded from their hospital registries. CGD was diagnosed with both functional and genetic analysis. Patients who had used voriconazole prophylaxis for six months or more after clinical and/or laboratory diagnosis of IFD were included in this study. Invasive fungal diseases were classified as proven, probable, or possible according to the revised criteria of the guideline.

**Results:** All seven patients were male. Two had an X-linked recessive subtype of CGD (X-CGD), and the others had autosomal recessive subtypes of CGD. The median age at diagnosis was 7 (4.5-19) years. *Aspergillus* spp was showed in three of patients. The median age at which first IFD oc-

## Öz

**Giriş:** Kronik granulomatoz hastalık (KGH) doğal bağışıklık sistemini etkileyen primer bağışıklık yetmezlik hastalığıdır. Bu hastalık bakteri ve fungus aracılığıyla hayatı tehdit eden veya tekrarlayan enfeksiyonlarla karakterizedir. KGH'li hastalarda ölümün en sık nedeni invaziv fungal hastalıklardır (IFH). İtrakonazol, yüksek IFH'ye sahip KGH'li hastalarda profilaksi için kullanılır. Ancak oral itrakonazol kullanımına hasta uyumu gastrointestinal yan etki nedeniyle düşüktür. KGH hastalarımızda IFD için uzun süreli vorikonazol profilaksisinin etkinliğini bildirmeyi hedefliyoruz.

**Gereç ve Yöntemler:** Bu geriye dönük çalışma yedi KGH hastasını içermektedir. Tüm veriler hastane kayıtlarından kaydedildi. KGH tanısı, fonksiyonel ve genetik analiz sonuçlarına göre konuldu. Klinik ve/veya laboratuvar olarak IFD tanısı konulduktan sonra, altı ay veya daha fazla sürede vorikonazol profilaksisi kullanılan hastalar bu çalışmaya dahil edildi. İnvaziv fungal hastalıklar, revize edilmiş kılavuz kriterlerine göre kanıtlanmış, olası veya muhtemel olarak sınıflandırılmıştır.

**Bulgular:** Yedi hastanın tamamı erkekti. İki tanesi X'e bağlı resesif KGH alt tipine (X-KGH) diğerleri otozomal resesif KGH alt tipine sahipti. KGH'nin ortanca tanı yaşı 7 (4.5-19) yıl idi. Üç hastada *Aspergillus* spp. kanıtlandı. İlk IFH'nin ortanca tanı yaşı 10 (4.5-19) yıl idi. Hastaların ortanca takip süresi 6 (3-16) yıl idi. Vorikonazol profilaksi sonrasında, altı hasta ikinci

## Correspondence Address/Yazışma Adresi

Şeyhan Kutluğ

Clinic of Immunology and Allergy,  
Batman Gynecology and Child Diseases Hospital  
Batman-Turkey

E-mail: seyhankutlug@hotmail.com

Received: 08.10.2020

Accepted: 22.11.2020

Available Online Date: 29.12.2021

©Copyright 2021 by Pediatric Infectious Diseases and Immunization Society.  
Available online at www.cocukenfeksiyon.org

curred was 10 (4.5-19) years. The median follow-up period was 6 (3-16) years. After voriconazole prophylaxis, 6 patients did not suffer from IFD second time. Only one patient, who has X-CGD, suffered from multiple fungal osteomyelitis and recurrent IFD despite undergoing voriconazole prophylaxis. Only one patient developed a lupus-like lesion in the cheek, which resolved after discontinuation of voriconazole prophylaxis.

**Conclusion:** Long-term voriconazole prophylaxis may be an alternative option in CGD patients with IFD in terms of patient compliance, efficacy and side effects.

**Keywords:** Chronic granulomatous disease, invasive fungal disease, primary immunodeficiency disease, prophylaxis, voriconazole

## Introduction

Chronic granulomatous disease (CGD) is a primary immunodeficiency disease that affecting the innate immune system. It is characterized by recurrent bacterial and fungal infections and inflammatory complications (1). It is caused by defective function of nicotinamide adenine dinucleotide phosphate (NADPH) oxidase, which is responsible for the production of phagocyte respiratory bursts and microbicidal reactive oxygen intermediates (ROIs) in phagocytic leukocytes (neutrophils, monocytes, eosinophils and macrophages) (2). Its prevalence is about 1 in 200,000 - 250,000 individuals (3,4). The NADPH oxidase system is a multicomponent enzyme complex with six subunits. One of these subunits, gp91<sup>phox</sup> [phagocyte oxidase (phox)], is encoded by CYBB, located on chromosome X (Xp21.1), and leads to X-linked recessive chronic granulomatous disease (X-CGD). The other five subunits are p22<sup>phox</sup>, p47<sup>phox</sup>, p67<sup>phox</sup>, p40<sup>phox</sup>, and C17ORF62 (EROS) which are encoded by CYBA, NCF1, NCF2, NCF4, and CYBC1 respectively, and they lead to autosomal recessive CGD (AR-CGD) (1,5). Glucose-6-phosphate dehydrogenase (G6PD) and Rac2 also affect NADPH oxidase activity (1,6).

Catalase-positive bacterial and/or fungal infections are usually the first manifestations of CGD at the time of diagnosis (7). Invasive fungal infection diseases (IFDs) are the most common causes of death among CGD patients (8,9). The frequency and mortality of IFDs among CGD patients have been reduced with the use of antifungal prophylaxis (10). Although antifungal therapies and prophylaxis have contributed to improvements in the survival rate of CGD patients with IFD during the last decade, the probability that CGD patients will contract an invasive fungal infection remains high (11).

New triazole antifungals for intravenous and oral use, including itraconazole, voriconazole and posaconazole, have been shown to benefit CGD patients (1,10). Intravenous voriconazole is recommended if an invasive fungal disease has been identified or is strongly suspected, while prophylactic itraconazole therapy is recommended for antifungal pro-

phylaxis in CGD patients (7,8) However, patients' compliance with itraconazole orally is low due to the gastrointestinal side effects (13,14). Recommendations regarding the dosage of posaconazole for long-term prophylaxis are not available for pediatric populations (15). Posaconazole is still not approved in children under 12 years of age (16). Voriconazole can be used in children over two years of age and patient compliance is better orally than itraconazole (13,14,16). For these reasons, we used voriconazole for fungal prophylaxis in CGD patients. However, there are no reports in the literature regarding the use of oral voriconazole for antifungal prophylaxis in CGD patients. That's why we wanted to report our experiences of CGD patients who underwent long-term voriconazole prophylaxis as well as their clinical and genetic characteristics.

**Sonuç:** Uzun süreli vorikonazol profilaksisi, hasta uyumu, etkinlik ve yan etkiler açısından IFH'li KGH hastalarında alternatif seçenek olabilir.

**Anahtar Kelimeler:** Kronik granulomatoz hastalık, invaziv fungal hastalık, primer immune yetmezlik hastalığı, profilaksi, vorikonazol

## Materials and Methods

This study is based on the investigated patients' medical records. Our CGD patients were diagnosed and followed at the Department of Pediatrics, Division of Pediatric Immunology and Allergy. Written informed consent was obtained from all patients and families. Diagnoses were made based on the results of dihydrorhodamine-1,2,3 (DHR) assay (1). A genetic analysis was conducted to make definitive diagnoses and determine each patient's subtype of CGD. The following patients were included in the study; those diagnosed with CGD by DHR measurement, those whose diagnosis was confirmed genetically, those who had invasive fungal disease, those who were received regular voriconazole prophylaxis for at least six months. Some patients were included to the previous reported multicenter study (8,17).

Invasive fungal diseases were classified as proven, probable, or possible according to the revised criteria of the European Organization for Research and Treatment of Cancer/ Invasive Fungal Infections Cooperative Group and the National Institute of Allergy and Infectious Diseases Mycoses Study Group (18). Co-trimoxazole prophylaxis was started for all patients when they were diagnosed with CGD. Voriconazole therapy was started when IFD occurred. After IFD therapy,

voriconazole prophylaxis was started as maintenance dosage. The following dosing regimens were used before 2016: on the first day, a loading dose of 6mg/kg q12h was administered, and then a maintenance dosage of 4 mg/kg q12h was administered each day afterwards (19). After 2015, we used the voriconazole dosage according to the guideline published in 2016 (20). Written informed consent was obtained from all patients and families. This retrospective study was approved by the Ethics Committee of Hospital of University with the protocol no: 2017/67.

### Results

Long-term prophylactic voriconazole prophylaxis was given to 7 CGD patients followed in our center (Table 1). All patients were male, and the median age at diagnosis was 7 (4.5-19) years. The median follow-up period was 6 (3-16) years. Parents of four patients had consanguineous marriage. Only one patient had a family history of CGD. All patients still suffered from IFD at follow-up, and *Aspergillus* spp. was detected in three of them. The causative agent could not be detected in four patients. In these patients, a possible fungal infection was diagnosed. The median age at which first IFD occurred was 10 (4.5-19) years. Thirteen IFD occurred in seven patients. IFDs

were proven in five (38%), probable in two (15%) and possible in six (46%) of the patients. All but one patients had IFD in the lung only. The other patient (P2) had IFD at multiple regions, including the lymph node, talus, ankle, vertebrae, subcutaneous tissue, and lung. Granulocyte colony-stimulating factor (G-CSF) was required for five patients, and interferon-gamma (IFN-γ) treatment was administered to three patients at follow-up. Hemopoietic stem cell transplantation (HSCT) was performed for three patients.

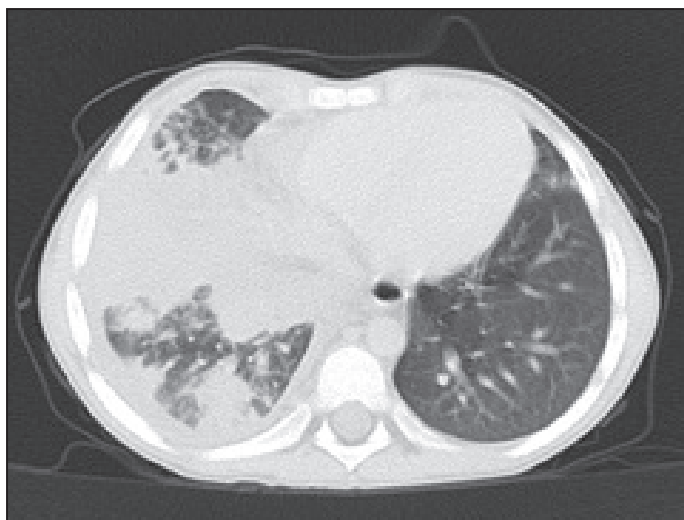Patient 1 was referred to us at 5.5 years of age because he was unresponsive to treatment for pneumonia. We detected possible IFD in his lung using thoracic computed tomography (Figure 1). We treated IFD after diagnosing CGD. Six months later, HSCT was performed. Patient 3 was referred to us at 4.5 years of age because he had pneumonia due to *Aspergillus fumigatus* infection, which was detected by a bronchoscopic biopsy. HSCT was performed thirty months after CGD diagnosis. Patients 1 and 3 continued co-trimoxazole and voriconazole prophylaxis until HSCT. Patient 2 presented with an ankle abscess and talar osteomyelitis due to *A. fumigatus* infection. But, he suffered from IFD in the lung due to *Aspergillus* spp. infection at follow-up despite undergoing voriconazole prophylaxis. HSCT was performed due to out-of-control IFD in

**Table 1.** Clinical and laboratory characteristics of CGD patients (n= 7)

Characteristics	Patient 1	Patient 2	Patient 3	Patient 4	Patient 5 <sup>a</sup>	Patient 6 <sup>a</sup>	Patient 7
Sex	Male	Male	Male	Male	Male	Male	Male
Age of onset of CGD	5 y	5 y	1 month	13 y	5 y	4 y	13 y
Diagnosis age via DHR	5.5 y	7 y	4.5 y	15 y	10 y	4 y	19 y
CGD subtype	X91 (X-CGD)	X91 (X-CGD)	A67 (AR-CGD)	A47 (AR-CGD)	A47 (AR-CGD)	A47 (AR-CGD)	A47 (AR-CGD)
Nucleotide change	c.676C>T	c.897G>T	c.279C>G + intron4+1G>C	c.75_76delGT	c.75_76delGT	c.75_76delGT	c.75_76 delGT
Age at first IFD	5.5 y	5.5 y	4.5 y	17 y	10 y	14 y	19 y
IFD's agent	Undetectable	<i>Aspergillus</i>	<i>Aspergillus</i>	Undetectable	<i>Aspergillus</i>	Undetectable	Undetectable
Fungus evidence level	Possible	Proven, Probable Possible	Proven	Possible	Proven	Possible	Possible
Duration of voriconazole prophylaxis	12 months	48 months	30 months	9 months	18 months	9 months	12 months
Other therapies	TMP/SMX G-CSF HSCT	TMP/SMX G-CSF HSCT	TMP/SMX G-CSF IFN-γ HSCT	TMP/SMX G-CSF IFN-γ	TMP/SMX G-CSF IFN-γ	TMP/SMX	-
Outcome	Alive	Deceased	Alive	Deceased	Alive	Alive	Alive
Current or death age	10 y	11 y	13	18 y	26 y	19 y	22 y
Reference	Published <sup>c</sup>	Published <sup>b</sup>	Published <sup>b</sup>	Published <sup>b</sup>	Published <sup>b</sup>	Published <sup>b</sup>	Not published

CGD: Chronic granulomatous disease, DHR: Dihydrorhodamine-1,2,3, X-CGD: X-linked recessive chronic granulomatous disease, AR-CGD: Autosomal recessive-linked chronic granulomatous disease, X91: X-linked gp91phox deficiency, A67: Autosomal recessive-linked p67phox deficiency, A47: Autosomal recessive-linked p47phox deficiency, IFD: Invasive fungal disease, G-CSF: Granulocyte colony-stimulating factor, TMP/SMX: Trimethoprim-sulfamethoxazole, IFN-γ: Interferon-gamma, HSCT: Hemopoietic stem cell transplantation.

a Patient 5 and patient 6 are brothers. b Reference 17. c Reference 8.

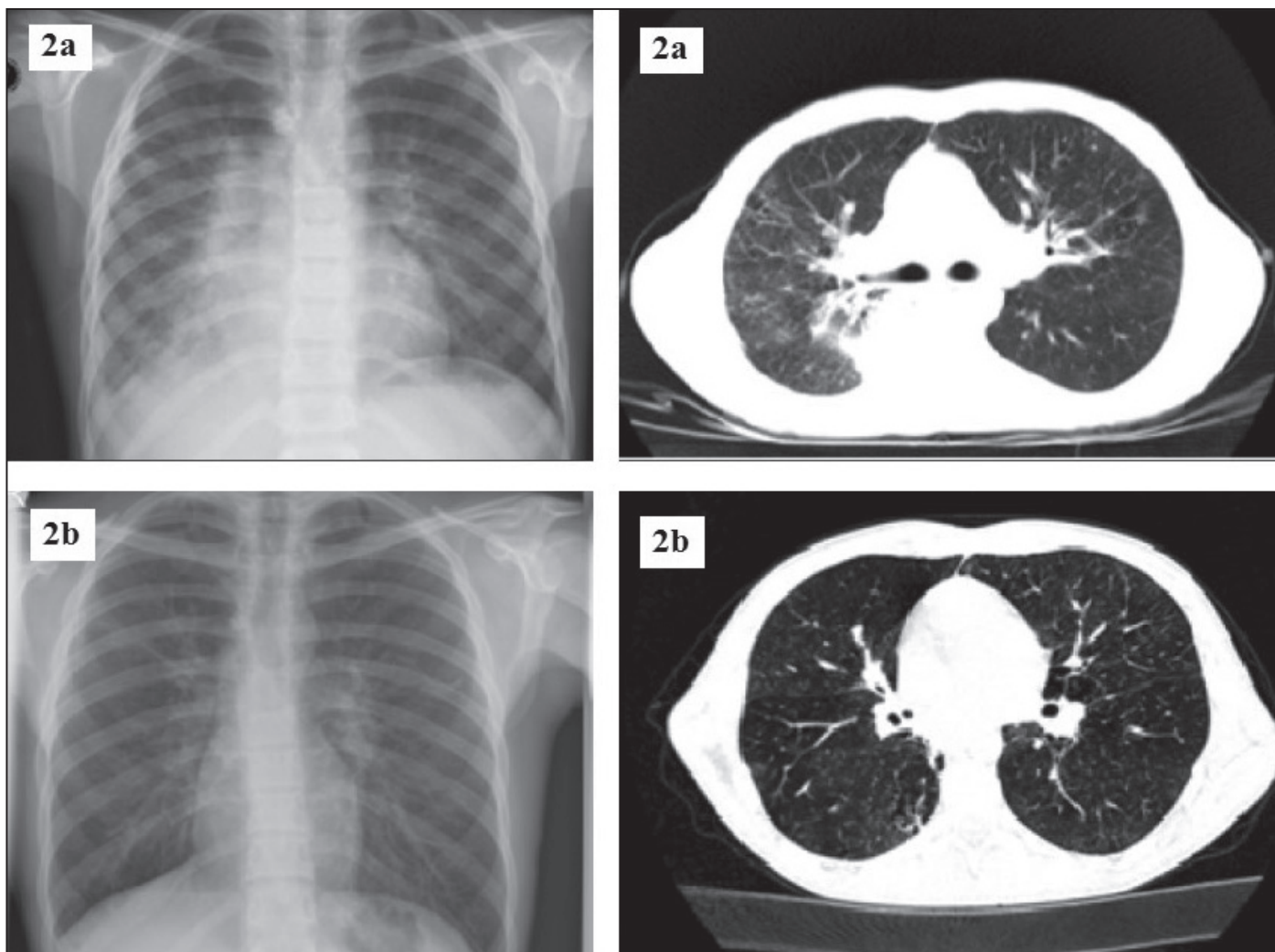


**Figure 1.** Chest computed tomography of Patient 1, demonstrating possible invasive fungal disease in the lung.

the lung. Unfortunately, he died just after HSCT due to respiratory and cardiac failure. We learned that Patients 2 and 3, in

whom *A. fumigatus* was found, kept poultry at home and were frequently exposed to a poultry house.

Patient 4 presented with multiple and recurrent liver abscesses due to *S. aureus* infection. He was also diagnosed with possible IFD in the lung. He did not suffer from IFD again after antifungal prophylaxis but he died due to empyema and pneumonitis caused by *S. aureus* infection. Patients 5 and 6 are brothers. Patient 5 presented with invasive pulmonary aspergillosis. Later, his brother (Patient 6) was diagnosed with CGD during the first pneumonia thought to be caused by IFD. They are doing well under voriconazole prophylaxis. Patient 7 was referred to us at 19 years of age because he was unresponsive to treatment for pneumonia, and he had recurrent tuberculosis. He had received tuberculosis lymphadenitis treatment when he was four years old, and lung tuberculosis treatment when 14 years old. When he was referred to us, he was also diagnosed with possible IFD in the lung (Figure 2a). After the diagnosis of CGD, IFD in the lung was treated with voriconazole. Later, voriconazole prophylaxis was started. At six months of



**Figure 2.** Chest X-ray and chest computed tomography before (2a) and after (2b) antifungal treatment of Patient 7.

prophylaxis, most of the lung findings were seen to regress (Figure 2b).

During the regular clinical visits of our patients, side effects related to voriconazole usage were questioned. Physical examination was performed and laboratory findings were examined. Hepatotoxicity (elevated transaminase levels, serum bilirubin, and alkaline phosphatase), visual disturbances, gastrointestinal system side effects, hallucinations, neuropathy, skin rash, electrocardiogram findings, PA chest radiographs were evaluated. No side effects were detected in any of the six patients. Lupus like syndrome developed in only sixth patient, so voriconazole prophylaxis was discontinued. Then the rash disappeared.

### Discussion

We reported our voriconazole prophylaxis experience and patient characteristics in seven CGD patients. This report provided important information about long-term voriconazole prophylaxis in CGD patients even if we have a small number of patients. Six of the seven patients who underwent long-term voriconazole prophylaxis have not suffered from IFD again. In addition, skin, gastrointestinal, and neurological side effects did not develop in any patient who received voriconazole prophylaxis for six months or more. Only one patient 6 developed a lupus-like lesion in the cheek, which resolved after treatment was discontinued.

Infection diseases are not only the main cause of the first manifestation of CGD at the time of diagnosis but also a major cause of morbidity and mortality among CGD patients (7,9). The most frequent pathogens that are responsible for morbidity and mortality in CGD patients are *Aspergillus* spp., *S. aureus*, *Serratia marcescens*, *Burkholderia cepacia*, *Nocardia* spp., and *Salmonella* spp. (9). IFD due to *Aspergillus* spp. is the most common cause of mortality in CGD patients (8,9). Recently, there has been a general increase in fungal infections, especially due to *Aspergillus* spp., in immunocompromised patients (21). Specifically, the occurrence of osteomyelitis due to *Aspergillus* spp. in CGD patients has doubled in the last decade (21). Additionally, invasive aspergillosis, a potentially life-threatening opportunistic infection that affects immunocompromised patients, accounts for more than 80% of IFDs (22). Therefore, antifungal prophylaxis should be effective against all infections caused by *Aspergillus* spp. However, we showed *Aspergillus* spp in only 5 out of 13 IFDs (%38). IFD due to *A. nidulans* is reportedly more difficult to control and is associated with the higher morbidity and mortality than other *Aspergillus* species (21). The *Aspergillus* species detected in our patients was *A. fumigatus*.

The use of itraconazole as a long-term antifungal prophylactic agent has been recommended for CGD patients (1,12,23). However, the variable bioavailability and poor tolerability

of oral itraconazole may limit its use as a prophylactic agent (13,14,24). In addition, the use of prophylactic itraconazole associated with an insidious pattern of infection requiring longer-term therapy, a higher proportion of infections due to *A. nidulans* and opportunistic fungi in CGD patients (11) and the need for other systemic antifungal agents, including caspofungin and liposomal amphotericin B, to treat allo-HSCT patients with IFD (14).

Voriconazole is a second-generation triazole that has potent and broad activity, is available both orally and intravenously, and has a low toxicity profile (25). It is approved for children two years and older. Voriconazole has been shown to be a reliable drug for antifungal prophylaxis therapy in children with primary (16,21) and secondary (26) immunodeficiency, and it was shown to be more effective than itraconazole for antifungal prophylaxis in HSCT patients (14). Furthermore, voriconazole has immunomodulatory effects (27). It has been used in the treatment of aspergillosis in the pediatric age group on the basis of experience and pharmacokinetic basis. Six of our patients did not suffer from IFD after starting long-term voriconazole prophylaxis. In adults, voriconazole is given twice daily at 6 mg/kg /dose for loading followed by 4 mg/kg/dose twice daily or 200 mg oral voriconazole twice daily for maintenance (16,20). The preferred pediatric dosage is substantially higher. Population pharmacokinetic analyzes of voriconazole suggest that children should be given an intravenous/oral loading dosage of 9 mg/kg/dose twice daily, and an intravenous/oral maintenance dosage at 8 mg/kg/dose twice daily (16,20). However, in younger adolescents (12-14 years), body weight is more important than age in predicting voriconazole pharmacokinetics (28). Therefore, young adolescents should be administered to children if their weight is <50 kg and to adults if their weight is ≥50 (16,20). In our case series, only one patient suffered from recurrent IFD despite long-term voriconazole prophylaxis, and we could not identify why this was the case. He had X-CGD, low residual oxidase capacity, and osteomyelitis due to *Aspergillus* spp. infection at two regions. In patients with very low residual oxidase capacity, voriconazole prophylaxis dosage may be insufficient (16,20). We administered G-CSF therapy to the patient, but we did not perform surgery because osteomyelitis was present at multiple regions (21,29).

Common reported side effects of voriconazole include gastrointestinal disorders (nausea, vomiting, diarrhea), hepatotoxicity (elevation of transaminase levels, serum bilirubin, alkaline phosphatase), visual disturbances (characterized principally by photopsia), hallucinations, neuropathy, central nervous system alterations (eg, memory loss, difficulty concentrating), headache, rash, skin rash, alopecia, erythroderma, photosensitivity, squamous cell carcinoma, long QT-syndrome. Voriconazole has variable serum concentration (27).

Mild to moderate visual impairment due to voriconazole has been reported, although it is non-serious and can be resolved without sequelae (14). Hepatotoxicity due to voriconazole is associated with very high voriconazole serum concentrations and different genotypes (30,31), and may increase together with other hepatotoxic drugs in leukemic and HSCT patients (14,30). We did not detect any visual impairment or hepatotoxicity in our patients. All new-generation azoles that are effective against *Aspergillus* spp. have wide inter- and intra-individual variability in terms of concentration in the blood (32). Therefore, through drug monitoring is recommended for itraconazole, voriconazole and posaconazole (15,30,32). Unfortunately, we cannot measure the voriconazole level in our patients. Alternatively, we regularly followed up the patients for signs and symptoms of voriconazole toxicity. Severe photosensitivity leading to squamous cell carcinoma and melanoma has been associated with long-term voriconazole treatment in a few adult CGD patients (33). One of our patients developed a lupus-like lesion on the cheek and it resolved after treatment was discontinued. Nevertheless, voriconazole should be carefully used for durations of more than 6-9 months in patients with risk factors for skin cancer (7).

Posaconazole is a new second-generation triazole. Only one study has investigated posaconazole prophylaxis for children with CGD, and so the recommended pediatric dosage has still not been determined (15). Welzen et al. reported that twice-daily doses of posaconazole for prophylaxis in 12 CGD patients was safe and resulted in no serious adverse events or breakthrough fungal infections, although it did cause skin rashes and gastrointestinal complaints (15). However, their patients were administered posaconazole for only 30 days, and the mean trough level was lower on day 30 than on day 10. This was likely due to clearance and less food intake; posaconazole has variable absorption depending on food intake (15,29). Moreover, the safe use of posaconazole in children under 12 years of age has not been approved (16). More studies are needed to investigate the use of posaconazole in CGD patients. Future studies should compare the efficacy of posaconazole and voriconazole prophylaxis in CGD patients.

The efficacy of prophylactic use of new triazole antifungals has usually been compared to that of other triazole antifungals in patients with secondary immunodeficiency, not in CGD patients, and the patients were followed for 100 days in some studies (13,14,25,34). We followed CGD patients undergoing long-term prophylaxis six months at least. In our experiences, long-term voriconazole prophylaxis was successful in five of the seven CGD patients in terms of development of IFD and side effects of voriconazole. However, this study is limited because of our inability to measure the trough levels of voriconazole. The fact that most of our patients had A47-related mutations, which is the mild form of CGD, may have successfully

demonstrated long-term voriconazole prophylaxis. Similar studies are needed in CGD patients with other mutations. Future studies should investigate more CGD patients and compare the efficacy of long-term voriconazole and posaconazole prophylaxis.

### Acknowledgments

Diagnostic study was financially supported by the TÜBİTAK (The Scientific and Technological Research Council of Turkey), Project No 114S352 and Erciyes University BAP TSA-2019-8322.

**Ethics Committee Approval:** This retrospective study was approved by the Ethics Committee of Ondokuz Mayıs University with the decision no: 2017/67.

**Peer-review:** Externally peer-reviewed.

**Author Contributions:** Concept - AY, ŞK; Design - AY, GŞ, AB; Supervision - AY; Data Collection and/or Processing - ŞK, ŞİKK, MYK; Analysis and/or Interpretation - ŞK, AY, GŞ, AB, MYK; Literature Review - ŞK, AY; Writing - ŞK, AY; Critical Review - All of authors

**Conflict of Interest:** All authors declare that they have no conflicts of interest or funding to disclose.

**Financial Disclosure:** The authors declared that this study has received no financial support.

### References

1. Roos D. Chronic granulomatous disease. *Br Med Bull* 2016;118(1):50-63. [CrossRef]
2. Kuhns DB, Alvord WG, Heller T, Feld JJ, Pike KM, Marciano BE, et al. Residual NADPH oxidase and survival in chronic granulomatous disease. *N Engl J Med* 2010;363(27):2600-10. [CrossRef]
3. Winkelstein JA, Marino MC, Johnston RB, Boyle J, Curnutte J, Gallin JI, et al. Chronic granulomatous disease report on a national registry of 368 patients. *Medicine (Baltimore)* 2000;79(3):155-69. [CrossRef]
4. Van den Berg JM, van Koppen E, Ahlin A, Belohradsky BH, Bernatowska E, Corbeel L, et al. Chronic granulomatous disease: the European experience. *PLoS One* 2009;4(4):e5234. [CrossRef]
5. Arnadóttir GA, Norddahl GL, Gudmundsdóttir S, Agustsdóttir AB, Sigurdsson S, Jensson BO, et al. A homozygous loss-of-function mutation leading to CYBC1 deficiency causes chronic granulomatous disease. *Nat Commun* 2018;9(1):4447. [CrossRef]
6. Roos D, de Boer M. Molecular diagnosis of chronic granulomatous disease. *Clin Exp Immunol* 2014;175(2):139-49. [CrossRef]
7. Chiriacco M, Salfa I, Di Matteo G, Rossi P, Finocchi A. Chronic granulomatous disease: Clinical, molecular, and therapeutic aspects. *Pediatr Allergy Immunol* 2016;27(3):242-53. [CrossRef]
8. Köker MY, Camcıoğlu Y, van Leeuwen K, Kılıç SŞ, Barlan I, Yılmaz M, et al. Clinical, functional, and genetic characterization of chronic granulomatous disease in 89 Turkish patients. *J Allergy Clin Immunol* 2013;132(5):1156-63. [CrossRef]
9. Marciano BE, Spalding C, Fitzgerald A, Mann D, Brown T, Osgood S, et al. Common severe infections in chronic granulomatous disease. *Clin Infect Dis* 2015;60(8):1176-83. [CrossRef]

10. Leiding JW, Holland SM. Chronic Granulomatous Disease In: Pagon RA, Adam MP, Ardinger HH, Wallace SE, Amemiya A, Bean LJH, Bird TD, Fong CT, Mefford HC, Smith RJH, Stephens K (eds). GeneReviews®. Seattle (WA): University of Washington Seattle, 1993-2016. 2012 (Updated 2016 Feb 11). Available from: <https://www.ncbi.nlm.nih.gov/pubmed/22876374>. [CrossRef]
11. Blumental S, Mouy R, Mahlaoui N, Bougnoux ME, Debré M, Beauté J, et al. Invasive mold infections in chronic granulomatous disease: a 25-year retrospective survey. *Clin Infect Dis* 2011;53(12):e159-e169. [CrossRef]
12. Seger RA. Modern management of chronic granulomatous disease. *Br J Haematol* 2008;140(3):255-66. [CrossRef]
13. Cornely OA, Maertens J, Winston DJ, Perfect J, Ullmann AJ, Walsh TJ, et al. Posaconazole vs. fluconazole or itraconazole prophylaxis in patients with neutropenia. *N Engl J Med* 2007;356(4):348-59. [CrossRef]
14. Marks DI, Pagliuca A, Kibbler CC, Glasmacher A, Heussel CP, Kantecki M, et al. Voriconazole versus itraconazole for antifungal prophylaxis following allogeneic haematopoietic stem-cell transplantation. *Br J Haematol* 2011;155(3):318-27. [CrossRef]
15. Welzen MEB, Bruggemann RJM, Van Den Berg JM, Voogt HW, Gilsen JH, Pajkrt D, et al. A twice daily posaconazole dosing algorithm for children with chronic granulomatous disease. *Pediatr Infect Dis J* 2011;30(9):794-7. [CrossRef]
16. Warris A, Lehrnbecher T, Roilides E, Castagnola E, Brüggemann RJM, Groll AH. ESCMID-ECMM guideline: Diagnosis and management of invasive aspergillosis in neonates and children. *Clin Microbiol Infect* 2019;25(9):1096-113. [CrossRef]
17. Kutluğ Ş, Şensoy G, Birinci A, Saraymen B, Köker MY, Yıldırım A. Seven chronic granulomatous disease cases in a single-center experience and a review of the literature. *Asian Pac J Allergy Immunol* 2018;36(1):35-41. [CrossRef]
18. De Pauw B, Walsh TJ, Donnelly JP, Stevens DA, Edwards JE, Calandrs T, et al. Revised definitions of invasive fungal disease from the European Organization for Research and Treatment of Cancer/Invasive Fungal Infections Cooperative Group and the National Institute of Allergy and Infectious Diseases Mycoses Study Group (EORTC/MSG) Consensus Group. *Clin Infect Dis* 2008;46(12):1813-21. [CrossRef]
19. Walsh TJ, Anaissie EJ, Denning DW, Herbrecht R, Kontoyiannis DP, Marr KA, et al. Treatment of aspergillosis: clinical practice guidelines of the Infectious Diseases Society of America. *Clin Infect Dis* 2008;46(3):327-60. [CrossRef]
20. Patterson TF, Thompson GR 3rd, Denning DW, Fishman JA, Hadley S, Herbrecht R, et al. Practice guidelines for the diagnosis and management of aspergillosis: 2016 Update by the infectious diseases society of America. *Clin Infect Dis* 2016;63(4):e1-e60. [CrossRef]
21. Dotis J, Roilides E. Osteomyelitis due to *Aspergillus* species in chronic granulomatous disease: an update of the literature. *Mycoses* 2011;54(6):e686-e96. [CrossRef]
22. Tsitsikas DA, Morin A, Araf S, Murtagh B, Johnson G, Vinnicombe S, et al. Impact of the revised (2008) EORTC/MSG definitions for invasive fungal disease on the rates of diagnosis of invasive aspergillosis. *Med Mycol* 2012;50(5):538-42. [CrossRef]
23. Gallin JI, Alling DW, Malech HL, Wesley R, Koziol D, Marciano B, et al. Itraconazole to prevent fungal infections in chronic granulomatous disease. *N Engl J Med* 2003;348(24):2416-22. [CrossRef]
24. Simon A, Besuden M, Vezmar S, Hasan C, Lampe D, Kreutzberg S, et al. Itraconazole prophylaxis in pediatric cancer patients receiving conventional chemotherapy or autologous stem cell transplants. *Support Care Cancer* 2007;15(2):213-20. [CrossRef]
25. Walsh TJ, Driscoll T, Milligan PA, Wood ND, Schlamm H, Groll AH, et al. Pharmacokinetics, safety, and tolerability of voriconazole in immunocompromised children. *Antimicrob Agents Chemother* 2010;54(10):4116-23. [CrossRef]
26. Zabalza A, Gorosquieta A, Equiza EP, Olavarria E. Voriconazole and its clinical potential in the prophylaxis of systemic fungal infection in patients with hematologic malignancies: a perspective review. *Ther Adv Hematol* 2013;4(3):217-30. [CrossRef]
27. Lat A, Thompson GR 3rd. Update on the optimal use of voriconazole for invasive fungal infections. *Infect Drug Resist* 2011;4(1):43-53. [CrossRef]
28. Friberg LE, Ravva P, Karlsson MO, Liu P. Integrated population pharmacokinetic analysis of voriconazole in children, adolescents, and adults. *Antimicrob Agents Chemother* 2012;56(6):3032-42. [CrossRef]
29. Falcone EL, Holland SM. Invasive fungal infection in chronic granulomatous disease: Insights into pathogenesis and management. *Curr Opin Infect Dis* 2012;25(6):658-69. [CrossRef]
30. Martin JM, Macias-Parra M, Mudry P, Conte U, Yan JL, Liu P, et al. Safety, efficacy, and exposure-response of voriconazole in pediatric patients with invasive aspergillosis, invasive candidiasis or esophageal candidiasis. *Pediatr Infect Dis J* 2017;36(1):e1-e13. [CrossRef]
31. Jin H, Wang T, Falcione BA, Olsen KM, Chen K, Tang H, et al. Through concentration of voriconazole and its relationship with efficacy and safety: A systematic review and meta-analysis. *J Antimicrob Chemother* 2016;71(7):1772-85. [CrossRef]
32. Andes D, Pascual A, Marchetti O. Antifungal therapeutic drug monitoring: Established and emerging indications. *Antimicrob Agents Chemother* 2009;53(1):24-34. [CrossRef]
33. Clancy CJ, Nguyen MH. Long-term voriconazole and skin cancer: is there cause for concern. *Curr Infect Dis Rep* 2011;13(6):536-43. [CrossRef]
34. Döring M, Eikemeier M, Cabanillas Stanchi KM, Hartmann U, Ebinger M, Schwarze CP, et al. Antifungal prophylaxis with posaconazole vs fluconazole or itraconazole in pediatric patients with neutropenia. *Eur J Clin Microbiol Infect Dis* 2015;34(6):1189-200. [CrossRef]