



Primary Subcutaneous Actinomycosis: A Case Report

Birincil Derialtı Aktinomikozu: Olgu Sunumu

Ahu Kara¹, Umut Çayıröz², Nuri Bayram¹, Hurşit Apa³, Banu Yaman⁴, Taner Akalın⁴, İlker Devrim¹

¹ Clinic of Pediatric Infectious Diseases, Dr. Behçet Uz Children Diseases and Surgery Training and Research Hospital, Izmir, Turkey

² Clinic of Infectious Diseases and Clinical Microbiology, Katip Celebi University, Izmir Atatürk Training and Research Hospital, Izmir, Turkey

³ Clinic of Pediatric Health and Diseases, Dr. Behçet Uz Children Diseases and Surgery Training and Research Hospital, Izmir, Turkey

⁴ Department of Medical Pathology, Ege University School of Medicine, Izmir, Turkey

Abstract

Actinomycosis is a chronic, suppurative, granulomatous and spreading disease which is caused by anaerobic bacteria of the family *Actinomycetaceae*. It is an endogenous infection and is induced by some predisposing factors that introduce *Actinomyces* species, which are the normal inhabitants of the host, into the mucosa. There are a variety of forms including cervico-facial, abdominal, toracic, pelvic, cerebral, and cutaneous actinomycosis. Cutaneous actinomycosis is extremely rare. Further more, actinomycosis is frequently undiagnosed or misdiagnosed and thus is not treated correctly. In most cases, definitive diagnosis is made after surgical resection. We present 9-year-old boy who was referred to our center with the complaint of back mass and the histopathological examination of excisional biopsy which was performed for excluding malignancy revealed actinomycosis.

Keywords: Actinomycosis, child, subcutaneous

Özet

Aktinomikoz, *Actinomycetaceae* ailesinde yer alan türlerin neden olduğu süregen, irinli, fistül oluşumuna yol açabilen ve yayılabilen bir hastalıktır. Aktinomikoz iç kaynaklıdır, normal floradaki *Actinomyces* türlerinin mukozaya girebilmesi sonucu oluşur. Boyun-yüz, karın, göğüs, pelvis, beyin ve deri aktinomikozu olmak üzere çeşitli biçimleri vardır. Deri biçimi oldukça seyrekdir. Aktinomikoz tanısında genellikle gecikilmekte ya da yanlış tanı konulmaktadır, buna bağlı olarak da yanlış tedavi uygulanmaktadır. Birçok olguda doğru tanı ancak cerrahi işlemden sonra konulabilmektedir. Bu yazıda, sırtındaki kitle nedeniyle getirilen, ayırıcı tanıda kötü doğallı hastalık düşünülen ve eksizyonel biyopsiyle tanı konulan, dokuz yaşındaki bir aktinomikoz olgusu sunulmuştur.

Anahtar Kelimeler: Aktinomikoz, çocuk, derialtı

Introduction

Defined for the first time in humans by Israel in 1878, actinomycosis is a chronic, communicable, purulent and fistula-forming disease caused by anaerobic, gram-positive bacteria belonging to the *Actinomycetacea* family (1,2). Types of *Actinomyces* are found as normal flora bacteria in the mucosa of the female reproductive system, digestive system and upper respiratory tract. *Actinomyces israelii* is considered the most

common type responsible for actinomycosis (3). Actinomycosis is encountered mostly between the ages of 15 and 35, 2-3 times more in the male population when compared to females and 10 times more in the rural region when compared to the urban zone (4,5). This paper aimed at presenting a case of actinomycosis brought to hospital for the mass on his back and whose differential diagnosis was thought to be a malignant disease and diagnosis could be made through excisional biopsy.

Correspondence Address / Yazışma Adresi:

Ahu Kara

Dr. Behçet Uz Çocuk Hastalıkları ve Cerrahisi Eğitim ve Araştırma Hastanesi,
Çocuk Enfeksiyon Kliniği, İzmir-Türkiye

E-mail: ahukara01@hotmail.com

©Copyright 2017 by Pediatric Infectious Diseases Society - Available online at www.cocukenfeksiyon.org

©Telif Hakkı 2017
Çocuk Enfeksiyon Hastalıkları Derneği - Makale metnine www.cocukenfeksiyon.org web sayfasından ulaşılabilir.

Case Report

A 9-year-old male patient was brought to hospital for back pain ongoing for a month and swelling on his back ongoing for two days. The patient, who did not have history of trauma, animal or human bite, was living in a village. Family history was normal. Physical examination of the patient revealed a rigid and fixed mass about 10 x 6 cm in size at the left side of his back under the scapula. The patient was admitted to hospital with a preliminary diagnosis of cellulitis due to the fact that there was tenderness, redness and a slight increase in temperature over and around the mass. Other systemic examinations of the patient were normal. Laboratory findings were as follows: C-reactive protein (CRP) 5.21 mg/dL (normal < 0.5 mg/dL), white blood cell count 15.370/mm³, and neutrophil count 11.160/mm³. The patient was started on ampicillin/sulbactam and clindamycin treatment. USG performed on the surface tissue of the mass detected a region in the subcutaneous soft tissue under the scapula whose heterogeneity and depth reached 2 cm with locally septa and irregular margins. Magnetic resonance imaging (MRI) revealed a pathological indicator, 63 x 59 mm in size, with irregular margins that showed contrast-material involvement in contrast series and that defaced fat plans between muscle masses at the back in a localization conforming to the upper section of the abdomen. Pathological signal and destruction profile were observed in adjacent ribs. Computed tomography (CT) was performed in order to determine bone involvement. A soft tissue structure, 80 x 35 mm in size, reaching to the intrathoracic region from the gap between the ribs and defacing muscle masses and fat plans in the left posterior thoracic wall was observed. Significant invasion or destruction in adjacent bone structures was not detected. Chest radiography of the patient was normal. There was no fever during follow-up. The mass on the back of the patient started to soften on the fifth day of treatment and the redness on the mass disappeared totally. Granule structures belonging to actinomycosis, surrounded by lymphocytes inside acute inflammatory granulation tissue rich in polymorphonuclear leukocytes and veins were monitored in the histopathological examination of the excisional biopsy sample taken from the mass. It was seen in histochemical screening that actinomycosis granules were stained positive with PAS and gram stains. (Figure 1). The treatment of the patient was maintained with penicillin via venous blood vessel. The treatment was designed to be completed to 6-12 months orally after the fourth week of treatment.

Discussion

Actinomycosis is a chronic disease caused by anaerobic types found in the *Actinomycetaceae* family in human and other warm-blooded animals. 34 species belonging to the

Actinomyces type have been defined until today and 21 of them have been reported to be clinically significant in humans (6). *Actinomyces israelii* is considered to be the most common type responsible for actinomycosis (3).

There are four forms of actinomycosis according to its localization in the body as neck-face, abdomen, chest and pelvic actinomycosis. Brain, skin involvement and disseminated actinomycosis are seen quite rarely. Purulence taken from the lesions, sputum, vaginal discharge, discharge, fistula content or tissue biopsy samples are analyzed for the diagnosis of actinomycosis. Since clinical symptoms and findings in actinomycosis are not endemic, diagnosis is usually delayed or incorrect (7). Correct diagnosis in many cases is reached after surgical intervention. Excisional biopsy was performed on the present case and probable malignant diseases were excluded.

Various other bacteria, tissue reaction structures surrounding this septic center and especially neutrophils are found in the yellowish-brownish particles (sulfur granules), < 1 mm in diameter, including *Actinomyces* nests in filamentous pattern in the purulent discharge of an actinomycosis lesion. Sulfur granules are formed, except from *Actinomyces*, by *Nocardia*, *Streptomyces* and by some staphylococci. Therefore, sulfur granules should not be accepted as an absolute characteristic ensuring the diagnosis of actinomycosis (8). Granules in actinomycosis include gram-positive bacteria non-resistant to acid (5). Sulfur granules of our patient were detected to be gram-positive and PAS positive.

Interventions as draining the abscesses or surgically removing the sinuses are the keystone approaches in the treatment of all clinical conditions of actinomycosis (9). It has been reported that the treatment of actinomycosis with penicillin was executed in the 1940s. Penicillin is still used in the treatment of actinomycosis today (10). 10-20 million units of penicillin G for 4-6 weeks through venous blood vessel and following this, 4-6 g/day phenoxymethyl orally is recommended. Oral treatment is reported to be maintained 6-18 months as regards the condition of the patient or until the lesions disappear (10).

Primary skin or soft tissue actinomycosis is a rarely encountered condition. Deterioration of skin integrity can be a promoter for the invasion of *Actinomyces* types. Valour et al. have reported a patient with edema in the ear and cellulite on the left side of the face that developed after acupuncture (11). In 1996, Coppens et al. reported actinomycosis in the posterior muscle of the femur in a patient with lung lesions (12). As it is seen in these cases, trauma or entrance site has been reported in many cases (13). Due to the fact that there was no trauma or bite history in our patient, mode of formation of actinomycosis could not be explained. Bose et al. have reported a 32-year-old female patient with a pus-like discharge on the left side of

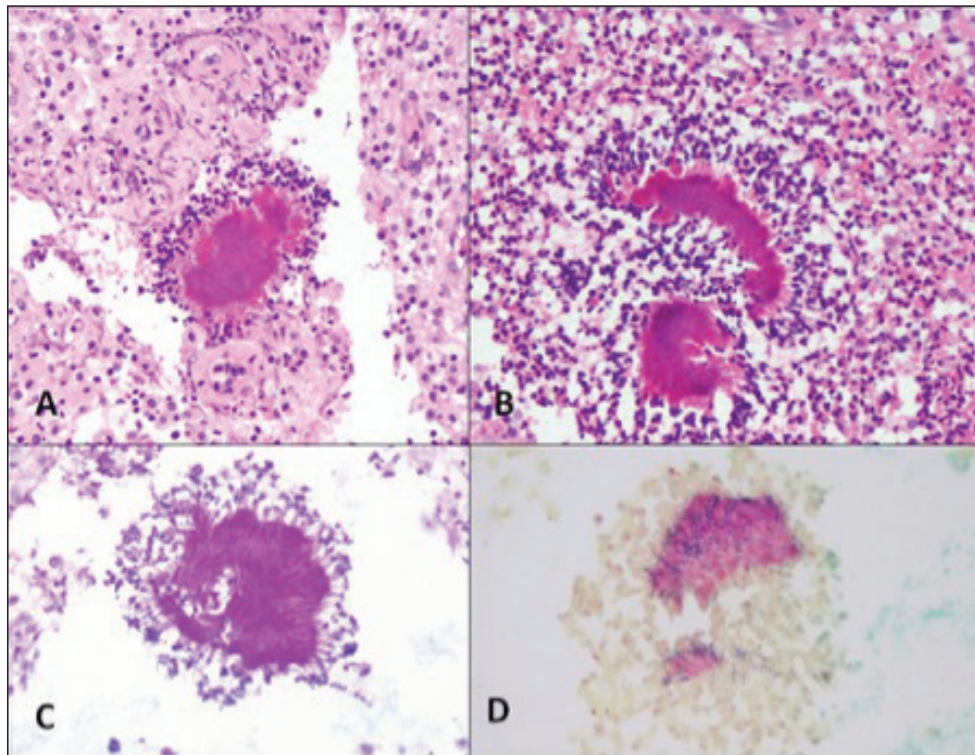


Figure 1. Actinomycosis granules positively stained with PAS and Gram stones surrounded by lymphocytes in acute inflammatory granulation tissue rich in abundant polymorphonuclear leukocytes.

her back and left armpit (14). A similar case has been reported by Roy et al. from Delhi, where the 26-year-old patient, who had lesions with purulent discharges in his upper left arm for one year, was diagnosed with actinomycosis and treated with penicillin (15).

All kinds of abscess, cellulite, folliculitis, subcutaneous fat necrosis perceived as mass and malignant formations, and tuberculosis that causes nodules with fistula and nocardiosis should be considered in differential diagnosis. Excisional biopsy performed on our patient ensured the correct diagnosis to be made without any delay.

Conclusion

Since subcutaneous actinomycosis is clinically similar to other infection diseases and malignant diseases, diagnosis, in a major part of the cases, is made after surgical intervention. In suspicious cases living in the countryside, actinomycosis should come to mind even though there is no history of trauma and biopsy should be performed to exclude malignant diseases and establish a final diagnosis.

Informed Consent: Written informed consent was obtained from the parents of the patient.

Peer-review: Externally peer-reviewed.

Author Contributions: Concept - İD; Design - İD; Supervision - İD, NB, HA; Collection and/or Processing - İD, AK, UÇ, BY, TA; Analysis and/or Interpretation - İD; Literature Review - AK; Writing - İD, NB, AK; Critical Review - İD, NB, HA.

Conflict of Interest: No conflict of interest was declared by the authors.

Financial Disclosure: The authors declared that this study has received no financial support.

References

1. Petrone LR, Sivalingam JJ, Vaccaro AR. Actinomycosis an unusual case of an uncommon disease. *J Am Board Fam Pract* 1999;12:158-61. [\[CrossRef\]](#)
2. Chaudhry SI, Greenspan JS. Actinomycosis in HIV infection: a review of a rare complication. *Int J STD AIDS* 2000;11:349-55. [\[CrossRef\]](#)
3. Wong VK, Turmezci TD, Weston VC. Actinomycosis. *BMJ* 2011; 343:d6099. [\[CrossRef\]](#)
4. Hillier S, Moncla B. Anaerobic gram-positive nonsporing bacilli and rods. Balows A (ed). *Manual of Clinical Microbiology*, 5. ed. Washington DC: WB Saunders, 1991:1700-1.

5. Beier KH, Rusnak RA. Unusual presentation of cervico-thoracic actinomycosis complicated by pericardial effusion: a case report. *J Emerg Med* 1997;15:303-7. [[CrossRef](#)]
6. Trevino Salinas EM, Martínez Palones JM, Pérez Benavente MA, Xercavins Montosa J. Pelvic actinomycosis in menopausal patient, case review. *Ginecol Obstet Mex* 2003;71:532-6. [[CrossRef](#)]
7. Ertan T, Kılıç M, Keşşaf Aşlar A, Yoldaş Ö, Göçmen E, Koç M. Actinomycosis of sigmoid colon: mimicking a colon cancer. *J Selcuk Faculty Med* 2005;22:63-6. [[CrossRef](#)]
8. Lee YM, Law WL, Chu KW. Abdominal actinomycosis. *ANZ J Surg* 2001;71:261-3. [[CrossRef](#)]
9. Karaarslan A. Actinomyces. Ustaçelebi Ş (ed). *Basic and Clinical Microbiology*. 1. ed. Ankara: Güneş Yay, 1999:457-61.
10. de Feiter PW, Soeters PB. Gastrointestinal actinomycosis: an unusual presentation with obstructive uropathy: report of a case and review of the literature. *Dis Colon Rectum* 2001;44:1521-5. [[CrossRef](#)]
11. Valour F, Sénéchal A, Dupieux C, et al. Actinomycosis: etiology, clinical features, diagnosis, treatment, and management. *Infect Drug Resist* 2014;7:183-97. [[CrossRef](#)]
12. Coppens L, Ibebeke B, Widelec J, Lustman F. Muscular actinomycosis in the back. *Acta Clin Belg* 1996;51:94-6. [[CrossRef](#)]
13. Reiner SL, Harrelsen JM, Miller SE, Hill GB, Gallis HA. Primary actinomycosis of an extremity: a case report and review. *Rev Infect Dis* 1987;9:581-9. [[CrossRef](#)]
14. Bose M, Ghosh R, Mukherjee K, Ghoshal L. Primary cutaneous actinomycosis: a case report. *J Clin Diagn Res* 2014;8:YD03-YD05. [[CrossRef](#)]
15. Roy D, Gupta Roy P, Misra PK. An interesting case of primary cutaneous actinomycosis. *Dermatol Online J* 2003;9:17. [[CrossRef](#)]