

Fungal Dilated Cardiomyopathy in a Patient with Acute Leukemia, How to Treat?

Aylin Canbolat Ayhan¹, Yusuf Ayhan², Çetin Timur¹, Müferet Ergüven¹

¹Clinic of Pediatric Hematology, İstanbul Göztepe Education and Research Hospital, İstanbul, Turkey

²Clinic of Pediatric Cardiology, İstanbul Göztepe Education and Research Hospital, İstanbul, Turkey

Abstract

Candida infection is an uncommon cause of myocarditis, endocarditis and dilated cardiomyopathy. It is well-known that the initiation time of antifungal treatment in these patients affects mortality rates. The optimal antifungal choice and duration of treatment for cardiac Candida infection is not yet well defined. In this report, a rare case of dilated cardiomyopathy and endocarditis due to *Candida albicans* in a 4-year-old child diagnosed with acute lymphoblastic leukemia is shared and its treatment is discussed.

(*J Pediatr Inf* 2014; 8: 82-5)

Keywords: Dilated cardiomyopathy, candida, acute leukaemia

Introduction

Invasive fungal infection is rare and commonly seen in patients with acute leukemia treated with cytotoxic drugs or in immunocompromised patients treated with broad spectrum antibiotics or corticosteroids. Fungal cardiac involvement is usually reported as endocarditis in the setting of a disseminated infection. On the other hand, fungal myocarditis or dilated cardiomyopathy is an exceedingly rare pathology and is frequently associated with overwhelming septicemia. The most frequently responsible pathogens are the *Candida* species (1, 2). However, the diagnosis is often difficult due to negative blood cultures, ineffective tests and scanty clinical findings of myocardial involvement. Herein, we present a case of dilated cardiomyopathy, myocarditis and endocarditis caused by *Candida albicans* which was treated successfully with caspofungin.

Acute Lymphoblastic Leukemia Berlin-Frankfurt-Munster (ALL-BFM) protocol and received first remission induction chemotherapy. On the 34th day of chemotherapy he developed a fever. His leucocyte count was $0.8 \times 10^9/L$, absolute neutrophil count was $0.1 \times 10^9/L$. C-reactive protein (CRP) was 24 mg/dL. Baseline biochemistry was normal. Blood from the port catheter and peripheral vein were sampled for cultures then intravenous empirical broad-spectrum antibiotics were initiated immediately. At this time, negative results were obtained for bacterial cultures. On the 6th day of fever antifungal therapy was initiated empirically. Serum galactomannan (GM) was screened twice per week and it was negative. Due to lack of availability beta-D-glucan test was not analysed. Amphotericin B deoxycholate (1 mg/kg/day) was initiated as the first line antifungal treatment but on the second day, because of a serious allergic reaction, treatment was switched to caspofungin with an initial loading dose 70 mg/m², followed by 50 mg/m²/day. Two days later, *Candida albicans* isolates were identified in blood as well as in the sample from a central line catheter. The organism was found to be sensi-

Received: 06.02.2013
Accepted: 25.04.2013
Available Online Date:
12.10.2013

Correspondence

Address:

Aylin Canbolat Ayhan, MD
Clinic of Pediatric
Hematology, İstanbul
Göztepe Education and
Research Hospital,
İstanbul, Turkey
Phone: +90 532 440 03 83
E-mail:
canbolataylin@hotmail.com

©Copyright 2014 by
Pediatric Infectious Diseases
Society - Available online at
<http://www.jpediatrinf.org>
DOI:10.5152/ced.2013.44



Case Report

A four-year-old boy, diagnosed with acute lymphoblastic leukemia, was treated by the

tive to amphotericin B but resistant to fluconazole. Despite the intensive antibacterial and antifungal therapy, the general condition of the patient deteriorated. A chest X-ray and high resolution computed tomographic scan of the thorax revealed bilateral non-specific infiltrations. Abdominal ultrasound showed multiple hepatic and splenic nodules supportive of candidiasis. Echocardiogram revealed a dilated left ventricle with impaired contractility; a 0.47x0.63 cm mobile mass on the catheter tip, and two vegetations measuring 1.11x0.82 cm and 0.71x0.96 cm on the right atrial wall (Figures 1, 2). Left ventricular diastolic dimension was 4.08 cm, systolic dimension was 3.39 cm with a fractional shortening of 17%. These findings met the definition of definite infective endocarditis according to the modified Duke criteria (3). The blood culture obtained from portacath tip and vegetation was positive for *Candida albicans* but antifungal susceptibility testing was not carried out. We decided to maintain antifungal therapy with caspofungin in combination with antibacterial (meropenem+vancomycin) therapy for 6 weeks. The patient's clinical status progressively improved. Blood cultures became negative on the 12th day of caspofungin treatment. Control echocardiography performed on the 19th day of antifungal therapy revealed almost complete recovery of cardiac function. Cardiac size and function returned to normal levels for the patient's age and size. Control abdominal ultrasound was performed on the same day and it revealed major regression in size and numbers of hepatosplenic nodules. On the fourth week of treatment hepatosplenic nodules completely disappeared. The treatment was continued until the end of the sixth week. At the end of this 6-week-treatment, physical examination of the child was completely normal. Abnormal echocardiographic, radiological, and ultrasonographic findings were all normalized. Left ventricular diastolic dimension was 3.63

cm, systolic dimension was 2.47 cm with a fractional shortening of 32%. Blood cultures became negative. After 6-weeks of antifungal treatment chemotherapy was reinitiated. Concurrent with chemotherapy oral voriconazole was initiated (4 mg/kg twice daily) to replace caspofungin with a view to maintaining antifungal therapy for a further 3 months. Oral voriconazole was our choice for secondary prophylaxis because the organism was found to be resistant to fluconazole. We initiated voriconazole at a dose of 6 mg/kg twice daily. He completed chemotherapy and did not have any fungal infection or cardiac complication later. He still remains in remission during a follow-up of 13 months.

Discussion

Fungal infection in immunocompromised pediatric patients is a life-threatening complication which affects the prognosis and increases mortality rates. Hematological malignancy, presence of central venous catheters, neutropenia and use of broad spectrum antibacterials are some of the risk factors for invasive fungal infections (4). In neutropenic patients 40% of fungal infections are disseminated and 70% or more of these are fatal despite aggressive antifungal therapy. *Candida* species are the most frequent causes of fungal endocarditis. Fungi account for 1%-6% of total endocarditis cases (5). It is usually reported in patients with intravascular prosthetic devices and patients undergoing open heart surgery (1). Candidiasis and aspergillosis may involve the myocardium and lead to myocarditis. Incidence rates for myocarditis in the setting of disseminated candidiasis range from 10% to 71% (2, 6). Dilated cardiomyopathy is very rare. In patients who are receiving chemotherapy dilated cardiomyopathy due to cardiotoxic agents is frequently experienced. Since our patient was not receiving high

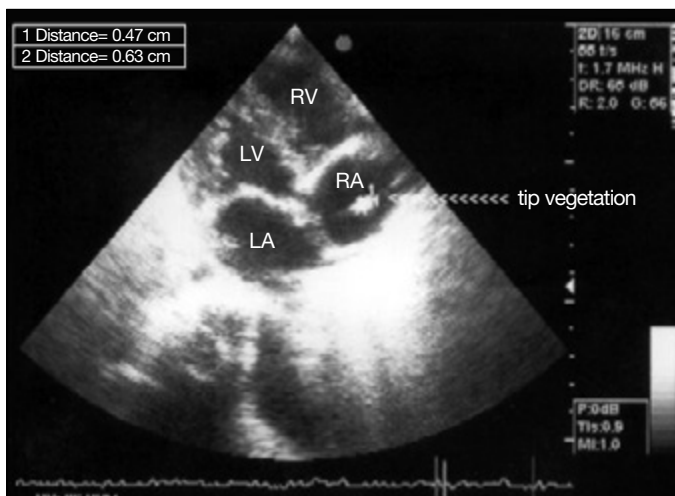


Figure 1. Echocardiography-tip vegetation

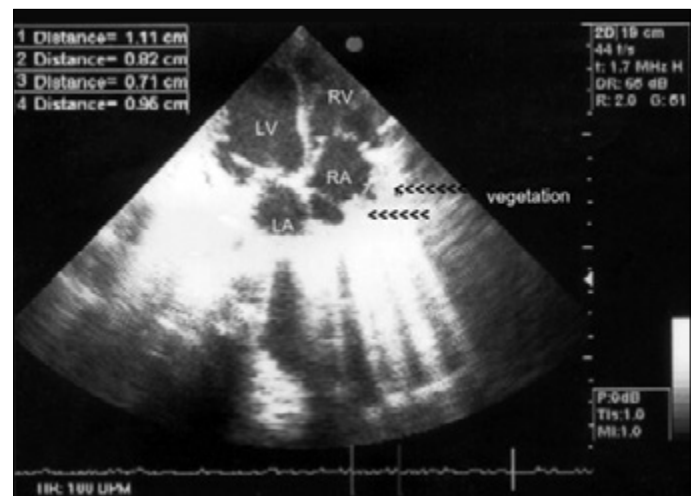


Figure 2. Echocardiography-vegetations on the right atrium wall

dose of anthracycline and an echocardiography was performed immediately after chemotherapy, the dilated cardiomyopathy was not related to cardiotoxicity of leukemia treatment. It is reported that candida endocarditis is usually diagnosed late after initial valvular colonization and when vegetations reach large sizes. This supports the suggestion that patients with candida bloodstream infection must be evaluated for cardiac involvement by echocardiography. The outcome of invasive fungal infection in pediatric febrile neutropenic patients is closely related to early diagnosis and early initiation of antifungal therapy. In our case the antifungal agent was initiated on the 6th day of the febrile neutropenia episode empirically. We believe that our early initiation of antifungal agent contributed to the complete recovery very strongly. Studies about optimal duration of antifungal therapy for fungal cardiac infections are very limited. The choice of an antifungal agent in febrile neutropenic patients is still controversial. In Ruping's study, caspofungin is recommended as the first-line and liposomal amphotericin B deoxycholate as the second-line antifungal choices for the empirical treatment of persistently febrile neutropenic patients (4). Infectious Diseases Society of America (IDSA) 2009 guidelines recommend intravenous amphotericin B with or without 5-fluorocytosine or an echinocandin as first-line treatment for *Candida* infective endocarditis and valve replacement is strongly recommended (7). An important limitation of our case was our insufficient antifungal susceptibility tests. Because of the present conditions of our laboratory only susceptibility tests for amphotericin B and fluconazole were studied. We did not know if the isolates of *Candida albicans* in our patient were susceptible or not to caspofungin and voriconazole. In Wang's study susceptibility to voriconazole and fluconazole was studied and reported that over 94% of the isolates of *C. albicans*, *C. tropicalis* and *C. parapsilosis* were susceptible to fluconazole and voriconazole (8). In the same study it is also reported that in 31.9% of uncommon *Candida* species was resistant to fluconazole and voriconazole (8). However, we did not have a chance to see if the species isolated in our patient was resistant to voriconazole or not. Surgery is mandatory in at least 30% of cases with infective endocarditis (9). According to guidelines complications where surgery should be considered are acute aortic or mitral regurgitation and congestive heart failure, evidence of perivalvular extension (locally uncontrolled infection), persistent infection after 7-10 days of adequate antibiotic therapy, infection due to microorganisms with a poor response to antibiotic treatment (fungi, *Brucella*, *Coxiella*, *Staphylococcus lugdunensis*), mobile vegetation >10 mm size before or during the first week of antibiotic treatment, recurrent emboli despite appropriate antibiotic therapy and

obstructive vegetations (9). We did not perform cardiac surgery on our patient because the sizes of vegetations were less than 10 mm, he did not have valve involvement and his haemodynamic status did not deteriorate. His clinical cardiac findings were due to myocarditis and impaired contractility. It was not related to valve regurgitation and subsequent congestive heart failure. According to the IDSA, guideline treatment should continue for at least 6 weeks after valve replacement and should continue for a longer duration with perivalvular abscesses and other complications (7). However, amphotericin itself may cause dilated cardiomyopathy and therefore its use should be carefully monitored (10). In our case amphotericin was used only for one day hence the cause for dilated cardiomyopathy was unlikely to be a drug toxicity.

There have been some reports of successful treatment of fungal endocarditis with caspofungin (11, 12). Similarly, in our patient caspofungin was also very effective in controlling the infection, and restoring the cardiac function. The patient recovered from overwhelming fungal sepsis completely and did not require valve replacement. Caspofungin was well tolerated. Duration of antifungal treatment for *Candida* infective endocarditis, especially for neutropenic patients having induction chemotherapy, is not clear. In addition, there is little data about fungal dilated cardiomyopathy and its treatment albeit in a study a 6-8 week treatment is recommended (1). In the same study the overall mortality rate of *Candida* infective endocarditis was 46.6% and 66.6% of patients were treated with caspofungin alone or in combination with other antifungal drugs (1). Our patient was treated for 6 weeks with intravenous caspofungin followed by oral voriconazole for the next 6 weeks for a total of 3 months to prevent the probable reactivation after restarting the chemotherapy and we think that this was effective since our patient did not have fungal reinfection. Some of the well-defined adverse reactions of voriconazole are transient visual disturbances usually as photopsia, hepatotoxicity, skin rash usually in sunlight-exposed areas and visual hallucinations (13). While our patient was using voriconazole we also followed him for these side effects very closely but we did not experience any adverse event during the treatment. Its oral administration was an advantage since we were able to discharge our patient home during this long treatment. Loading regimens in pediatric patients have not been adequately studied but because of the more accelerated metabolic clearance in pediatric patients, the European Medicines Agency recommends a maintenance dosage of 7 mg/kg twice daily in pediatric patients for the attainment of plasma levels comparable to adults' (13). In our patient we preferred to initiate voriconazole with a lower dose such as 6 mg/kg twice daily and in spite of this we think that it was very effective.

Central venous catheters are a major source of entry for candidemia, atypical mycobacteria infection and persistent bacteremia; and therefore, in addition to treatment of the infective conditions removal of the central catheter is also recommended (7). In our patient the portacath was considered to be the source of the infection and therefore it was removed.

Conclusion

Our case suggested that dilated cardiomyopathy and endocarditis due to candida albicans in immunocompromised patients could be treated effectively with caspofungin and it could be considered as the first line treatment in such patients. However further prospective studies are required to confirm our findings.

Informed Consent: Written informed consent was obtained from patients who participated in this study.

Peer-review: Externally peer-reviewed.

Author Contributions: Concept - A.C.A., Y.A.; Design - A.C.A., Y.A.; Supervision - A.C.A., Y.A.; Funding - A.C.A., Y.A.; Materials - A.C.A., Y.A., Data Collection and/or Processing - A.C.A., Y.A., C.T., M.E.; Analysis and/or Interpretation - A.C.A., Y.A., Literature Review - A.C.A., Writing - A.C.A.; Critical Review - A.C.A., Y.A.; Other - A.C.A.

Conflict of Interest: No conflict of interest was declared by the authors.

Financial Disclosure: The authors declared that this study has received no financial support.

References

1. Falcone M, Barzaghi N, Carosi G, et al. Candida infective endocarditis. *Medicine* 2009; 88: 160-8. [\[CrossRef\]](#)
2. Nosanchuk JD. Fungal myocarditis. *Frontiers in Bioscience* 2002; 7: 1423-38. [\[CrossRef\]](#)
3. Li JS, Sexton DJ, Mick N, et al. Proposed modifications to the Duke criteria for the diagnosis of infective endocarditis. *Clin Infect Dis* 2000; 30: 633-8. [\[CrossRef\]](#)
4. Ruping MJ, Vehreschild JJ, Cornely OA. Patients at high risk of invasive fungal infections: when and how treat. *Drugs* 2008; 68: 1941-62. [\[CrossRef\]](#)
5. Pierrotti LC, Baddour LM. Fungal endocarditis. *Chest* 2002; 122: 302-10. [\[CrossRef\]](#)
6. Rubinstein E, Noriega E, Simbekoff M, et al. Fungal endocarditis: analysis of 24 cases and review of the literature. *Medicine* 1975; 54: 331-4.
7. Pappas PG, Kauffman CA, Andes D, et al. Clinical practice guidelines for the management of candidiasis: 2009 update by the Infectious Diseases Society of America. *Clin Infect Dis* 2009; 8: 503-35. [\[CrossRef\]](#)
8. Wang H, Xiao M, Chen SC, et al. In vitro susceptibilities of yeast species to fluconazole and voriconazole as determined by the 2010 National China Hospital Invasive Fungal Surveillance Net (CHIF-NET) study. *J Clin Microbiol* 2012; 50: 3952-9. [\[CrossRef\]](#)
9. Horstkotte D, Follath F, Gutschik E, et al. Guidelines on prevention, diagnosis and treatment of infective endocarditis executive summary; the task force on infective endocarditis of the European society of cardiology. *Eur Heart J* 2004 Feb; 25: 267-76. [\[CrossRef\]](#)
10. Danaher PJ, Cao MK, Anstead GM, et al. Reversible dilated cardiomyopathy related to amphotericin B therapy. *J Antimicrob Chemother* 2004; 53: 115-7. [\[CrossRef\]](#)
11. Bacak V, Biocina B, Starcevic B, et al. Candida albicans endocarditis treatment with caspofungin in an HIV-infected patient-case report and review of literature. *J Infect* 2006; 53: 11-4. [\[CrossRef\]](#)
12. Rajendram R, Alp NJ, Mitchell AR, et al. Candida prosthetic valve endocarditis cured by caspofungin therapy without valve replacement. *Clin Infect Dis* 2005; 40: 72-4. [\[CrossRef\]](#)
13. Walsh TJ, Anaissie EJ, Denning DW, et al. Treatment of Aspergillosis: Clinical Practice Guidelines of the Infectious Diseases Society of America. *Clin Infect Dis* 2008; 46: 327-60. [\[CrossRef\]](#)